JOURNAL OF COSMETIC AND LASER THERAPY
https://doi.org/10.1080/14764172.2018.1481511

Taylor & Francis
Taylor & Francis Group

ORIGINAL ARTICLE

Broadband light treatment using static operation and constant motion techniques for skin tightening in Asian patients

Seunggyun In[a], Henry Park[b], Heejin Song[a], Jiho Park[c], Heesu Kim[c], and Sung Bin Cho [c,d]

[a]Human Dermatology Clinic, Incheon, Korea; [b]Institute for Healthcare and Life Science, International St. Mary's Hospital, Catholic Kwandong University College of Medicine, Incheon, Korea; [c]Department of Dermatology and Cutaneous Biology Research Center, International St. Mary's Hospital, Catholic Kwandong University College of Medicine, Incheon, Korea; [d]Kangskin Dermatology Clinic, Seoul, Korea

ABSTRACT

Background: Broadband light (BBL) devices irradiate photons of different wavelength to induce photothermal reactions on various aging-related chromophores.
Objectives: To evaluate three BBL treatment settings for skin tightening in Asian patients.
Methods: A total of 27 patients underwent three sessions of BBL treatment via (1) an 800-nm cutoff filter using a static operation technique and a 695-nm cutoff filter using a constant motion technique (group 1, $N = 9$), (2) an 800-nm cutoff filter using a constant motion technique (group 2, $N = 9$), and (3) a 590-nm cutoff filter using a constant motion technique (group 3, $N = 9$).
Results: The patients in group 1 presented marked clinical improvements in zygomatic wrinkles, nasolabial folds, and marionette lines, with a median overall global aesthetic improvement scale (GAIS) score of 3. Meanwhile, patients in group 2 exhibited noticeable improvements in zygomatic wrinkles, nasolabial folds, perioral expression wrinkles at the cheek, and marionette lines, with a median GAIS score of 3. Patients in group 3 experienced improvement in skin tone and texture, zygomatic wrinkles, nasolabial folds, and marionette lines, with a median GAIS score of 2.
Conclusions: Our data demonstrated that BBL treatment for nonablative, noninvasive skin tightening elicits satisfactory clinical outcomes.

ARTICLE HISTORY
Received 4 January 2018
Accepted 20 May 2018

KEYWORDS
Broadband light; skin tightening; skin laxity; cutoff filter; static operation technique; constant motion technique

Introduction

Pulses of broadband light (BBL) emit photons of differing wavelengths that propagate to various key chromophores at different depths in the skin (1–4). The absorption of BBL by chromophores, including water, melanin, and oxyhemoglobin, induces selective, photobiologic tissue reactions via photothermolysis (2,3). Thereby, high-intensity, pulsed, and polychromatic light sources emitted by BBL systems at a millisecond pulse duration exert therapeutic effects on several pigmented and vascular disorders, hypertrichotic hair disorders, and skin aging (1,4–6). Additionally, noninvasive and nonablative BBL therapy for skin rejuvenation can also achieve concomitant improvements in skin texture and wrinkles (4–6).

Treatment with BBL elicits numerous effects on the skin. High-intensity BBL energy activates fibroblasts that induce the production of type I and type III collagen and rearranges collagen and elastic fibers (7–9). After BBL treatment, gene expression patterns in aged cells and tissues can be restored to that of young cells and tissues, and impaired cellular integrity in aged cells can be recovered (10). Furthermore, BBL treatment downregulates increased expression of aging-related protein biomarkers, such as vimentin and its advanced glycosylation end products, in human dermal microvascular endothelial cells (7).

Technological advances have allowed BBL systems to irradiate well-controlled, high-intensity, polychromatic light energy to aging skin for skin tightening. However, because of the great number of potential combinations of treatment parameters, including cutoff filter, pulse duration and frequency, intensity/fluence, and static/constant motion delivery technique, optimized treatment settings have not been fully elucidated. In this study, we sought to evaluate three BBL treatment settings for nonablative and noninvasive tightening of the facial and neck skin in Asian patients: (1) BBL treatment via an 800-nm cutoff filter using a static operation technique and a 695-nm cutoff filter using a constant motion technique (group 1); (2) BBL treatment via an 800-nm cutoff filter using a constant motion technique (group 2); and (3) BBL treatment via a 590-nm cutoff filter using a constant motion technique (group 3). The three groups of Asian patients were treated separately with three sessions of BBL treatment at 2-week intervals using the respective treatment settings, and therapeutic outcomes were evaluated according to assessment parameters of the upper face, mid-face, and lower face. Additionally, posttreatment changes in overall skin texture, pigmented lesions, and vascular lesions were assessed objectively.

CONTACT Sung Bin Cho, drsbcho@gmail.com Department of Dermatology and Cutaneous Biology Research Center, International St. Mary's Hospital, Catholic Kwandong University College of Medicine, 25 Simgok-ro, Seo-gu, Incheon 22711, Republic of Korea

Color versions of one or more of the figures in the article can be found online at www.tandfonline.com/ijcl.

Materials and methods

Patients

In total, 27 Korean female patients (median age, 38 years; interquartile range [IQR], 32–45 years; age range, 25–63 years) with Fitzpatrick skin type III–IV were scheduled to undergo static operation or constant motion delivery of BBL energy for skin tightening. Patients were excluded from this study if they had received systemic or topical retinoid therapy, skin resurfacing procedures (chemical peeling or mechanical- or laser-assisted dermabrasion), fractional laser treatment (nonablative or ablative), radiofrequency treatment (monopolar or bipolar; noninvasive or invasive), intensity focused ultrasound treatment, botulinum toxin injection, thread implantation, injection therapy with fillers or tissue activators, or face-lift surgery within the last 6 months. Moreover, patients with a high probability of becoming pregnant or a propensity for photosensitive dermatitis, keloids, or immunosuppression were excluded. This study was approved by the Institutional Review Board of International St. Mary's Hospital, Catholic Kwandong University College of Medicine, Incheon, Republic of Korea.

Broadband light therapy

After obtaining written informed consent, all participants were treated with three sessions of BBL energy treatment using SkinTyte II™ (BBL™; Sciton, Palo Alto, CA, USA) at 2-week intervals. Each treatment session began by gently cleansing the face and neck with a mild soap and 70% ethanol, after which chilled, colorless ultrasonic gel was applied thereto without pretreatment with topical or systemic anesthesia. BBL treatment was performed using three different treatment settings as follows. To group 1 (N = 9), two passes of 50 BBL pulses (a total of 100 pulses/session) were delivered on the face and submental part of the neck via an 800ST cutoff filter (Sciton) at a fluence of 52 J/cm^2, an exposure time of 5 s, and a cooling crystal temperature of 12°C using a static operation technique (Table 1, Figure 1a). Immediately after the 800ST treatment, additional treatment was delivered with the 695ST cutoff filter (Sciton), intensity of 12 W/cm^2, exposure time of 10 s, and cooling crystal temperature of 25°C using a constant motion technique as shown in Figure 1b. The estimated total energy accumulation for 695-nm-filtered treatment was approximately measured as 10,000 J/session for a surface temperature of 40–42°C (treatment end point). To group 2 (N = 9), BBL treatment was performed with the 800ST cutoff filter (Sciton), an intensity of 10 W/cm^2, an exposure time of 10 s, and a cooling crystal temperature of 25°C using a constant motion technique. Therein, the estimated total energy accumulation was measured approximately as 30,000 J/session at a surface temperature of 40–42°C. To group 3 (N = 9), BBL treatment was delivered on the face and submental part of the neck via a 590ST cutoff filter (Sciton) at an intensity of 12 W/cm^2, an exposure time of 12 s, and a cooling crystal temperature of 25°C using a constant motion technique. Therein, the estimated total energy accumulation for 590ST treatment was approximately 30,000 J/session at a surface temperature of 40–42°C. During the BBL treatments using the constant motion technique, a Smoothie Adapter™ (Sciton) was adapted to the BBL handpiece to cover the sides and edges of the crystal. After treatment, the treated areas were cooled with icepacks. No prophylactic systemic corticosteroids or antibiotics were prescribed. The patients were recommended to apply broadband sunscreens and emollients and to avoid topical bleaching and retinoid agents during the three sessions of treatment and the follow-up period.

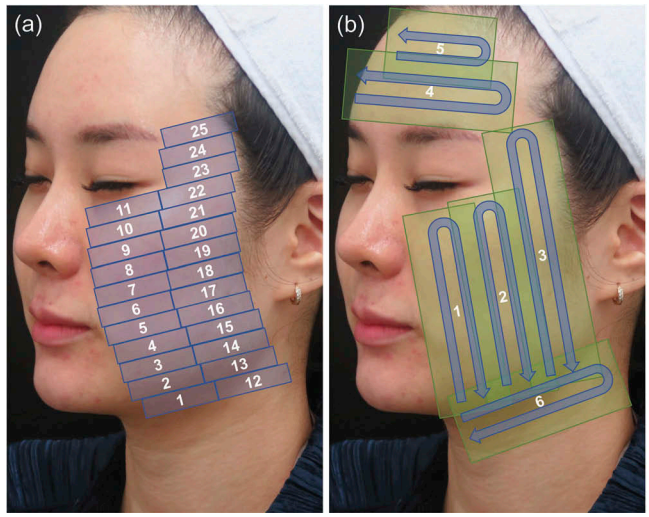

Figure 1. Broadband light (BBL) treatment using static operation and constant motion delivery techniques. Schematic views of BBL pulse lines on the face and submental part of the neck using an 800-nm cutoff filter and a static operation technique (a) and pulse strings using a 695-nm cutoff filter and a constant motion operation technique (b) in a left oblique view. Numbers reflect the sequences of BBL pulse delivery. Arrows reflect the direction of the constant motion technique.

Objective clinical assessment

At baseline, 2 weeks after each treatment session, and 2 months after the final treatment, digital photographs were taken with the patients placed in an identical position and under the same light settings using a digital camera. Thereafter, two investigators

Table 1. Nonablative and noninvasive tightening of the facial and neck skin in Asian patients with broadband light treatment using three different treatment settings.

Group	Cutoff filter (nm)	Fluence (J/cm^2)	Intensity (W)	Number of pulses	Exposure time (sec)	Total accumulation energy (J)	Cooling (°C)	Technique
1	800	52		100	5		12	Static operation
	695		10		12	10,000	25	Constant motion
2	800		10		10	30,000	25	Constant motion
3	590		12		12	30,000	25	Constant motion

objectively evaluated the effects of BBL treatment for skin tightening by analyzing the photographs. Clinical improvement was assessed by evaluating signs of aging along the upper face (eyebrow ptosis, blepharochalasis, and horizontal forehead lines), the mid-face (zygomatic wrinkles or mid-cheek furrows, nasolabial folds, and perioral expression wrinkles at the cheek), and the lower face (marionette lines and jowl sagging). All assessment parameters were scored on the face according to the global aesthetic improvement scale (GAIS) as "worse than before" (score: −1), "not applicable or clinically unchanged" (score: 0), "slightly improved" (score: 1), "moderately improved" (score: 2), "markedly improved" (score: 3), or "near totally improved" (score: 4). Overall clinical improvement was objectively scored using GAIS at 2 months after the final treatment. Additionally, patients were surveyed to subjectively report their rate of satisfaction with treatment as "unsatisfied" (score: 0), "slightly satisfied" (score: 1), "satisfied" (score: 2), and "very satisfied" (score: 3). Any side effects, including burn, scaling, crusting, prolonged erythema, post-therapy dyschromia, and scarring, were also evaluated throughout the course of treatment and follow-up.

Results

Combined BBL treatment using 800ST static operation and 695ST constant motion techniques

The patients in group 1 (median age, 32 years; IQR, 27–33 years; age range, 25–38 years) were treated with BBL via the 800ST-cutoff filter using a static operation technique and the 695ST-cutoff filter using a constant motion technique. At 2 months after the final treatment, the patients presented remarkable clinical improvements in overall skin texture and tone, facial contours, and wrinkles, with a median overall GAIS score of 3 (IQR, 2–3). Moreover, the median GAIS scores were 1 (IQR, 1–2) in the upper face, 3 (IQR, 2–3) in the mid-face, and 2 (IQR, 1–2) in the lower face. Among the assessment parameters, zygomatic wrinkles or mid-cheek furrows, nasolabial folds, marionette lines, and jowl sagging were found to have markedly improved (Figures 2 and 3).

Additionally, most of the patients reported that clinical improvements in overall skin texture and fine wrinkles were noticeable within 3 days, and the patients' median satisfaction rate at posttreatment 2 months was 2 (IQR, 1–3). None of the patients experienced transient or prolonged darkening of the epidermal or dermal pigmented lesions, including lentigines or melasma. Furthermore, no other major side effects, including oozing, scaling, crusting, burn, secondary skin infection, prolonged edema or erythema, post-therapy hyperpigmentation or hypopigmentation, and scarring, were encountered.

BBL treatment using the 800ST constant motion technique

In group 2, the patients (median age, 45 years; IQR, 40–62 years; age range, 32–63 years) were treated with BBL via the 800ST-cutoff filter using a constant motion technique. At 2 months posttreatment, remarkable clinical improvements were found in the overall skin texture, contour of the face, and fine and coarse wrinkles, with a median overall GAIS score of 3 (IQR, 2–3).

Figure 2. Photographs of a 25-year-old female patient (a, c) at baseline and (b, d) at 2 months after three sessions of BBL treatment via the 800ST cutoff filter using a static operation technique and the 695ST cutoff filter using a constant motion technique. Remarkable clinical improvement in zygomatic wrinkles, nasolabial folds, marionette lines, and jowl sagging is apparent. (a, b) Anterior view, (c, d) left lateral view.

Moreover, the median GAIS scores of each objective assessment parameter were 1 (IQR, 0–1) in the upper face, 3 (IQR, 1–3) in the mid-face, and 2 (IQR, 2–3) in the lower face. Among the aging-related parameters, zygomatic wrinkles or mid-cheek furrows, nasolabial folds, perioral expression wrinkles at the cheek, marionette lines, and jowl sagging were found to have notably improved (Figure 4). Additionally, most of the patients reported clinical improvement in overall skin texture and fine wrinkles noticeable within 3 days, and the patients' median satisfaction rate at 2 months after the final treatment was 2 (IQR, 1–3). None of the patients experienced transient or prolonged worsening of pigmented disorders or any other major side effects.

BBL treatment using the 590ST constant motion technique

In group 3, the patients (median age, 41 years; IQR, 36–45 years; age range, 27–60 years) were treated with BBL via the 590ST-cutoff filter using a constant motion technique. At 2 months after the final treatment, patients exhibited marked clinical improvements in overall skin texture, skin tone, and fine wrinkles, with a median GAIS score of 2 (IQR, 2–3). The median GAIS scores of assessment parameters were 1 (IQR, 1–2) in the upper face, 3 (IQR, 2–3) in the mid-face, and 2 (IQR, 2–2) in the lower face.

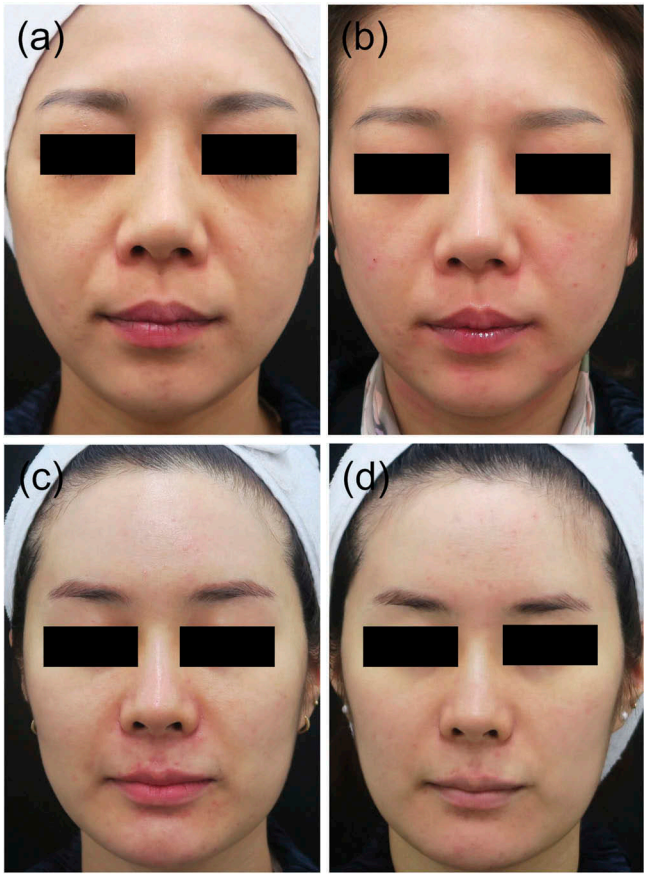

Figure 3. Photographs of (a, b) 35-year-old and (c, d) 32-year-old female patients (a, c) at baseline and (b, d) at 2 months after three sessions of BBL treatment via the 800ST cutoff filter using the static operation technique and 695ST-cutoff filter using the constant motion technique. Marked clinical improvement in zygomatic wrinkles, nasolabial folds, marionette lines, and jowl sagging is noted. Anterior view.

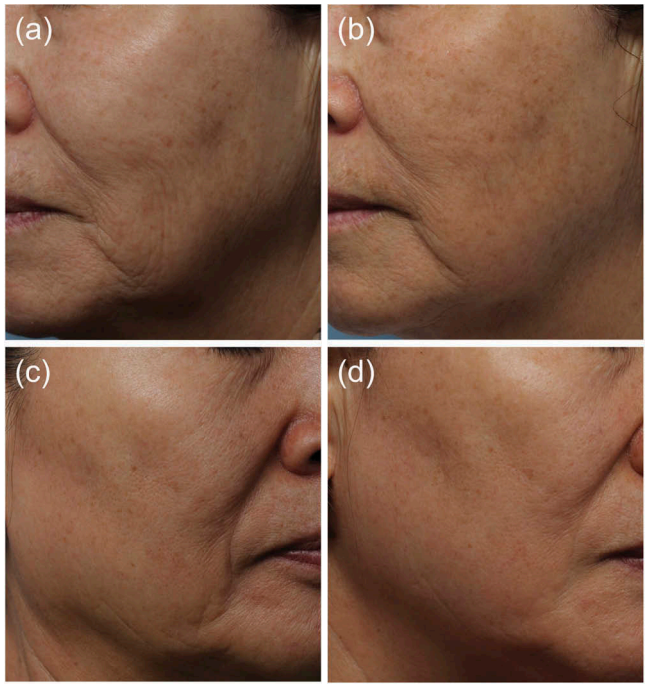

Figure 4. Photographs of a (a, b) 63-year-old and (c, d) another 63-year-old female patient (a, c) at baseline and (b, d) at 2 months after three sessions of BBL treatment via the 800ST cutoff filter using the constant motion technique. Zygomatic wrinkles, nasolabial folds, perioral expression wrinkles at the cheek, marionette lines, and jowl sagging had noticeably improved. (a, b) Left oblique view, (c, d) right oblique view.

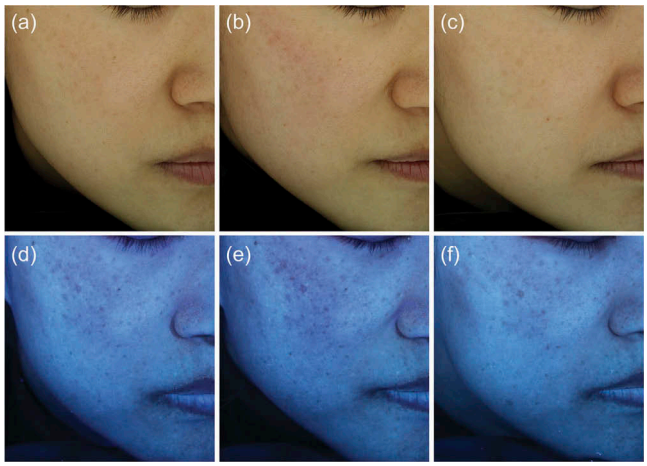

Figure 5. Photographs of a 36-year-old female patient (a, d) at baseline, (b, e) immediately after the first session of BBL treatment, and (c, f) 2 months after three sessions of BBL treatment via the 590ST cutoff filter using the constant motion technique. (b, e) Transient darkening of melasma and epidermal pigmented lesions and posttreatment erythema were found immediately after BBL treatment. (c, f) Overall skin tone and pigmented lesions improved after the third BBL treatment. Right oblique view; photographs were taken under (a–c) normal and (d–f) ultraviolet light exposure.

Particularly, zygomatic wrinkles or mid-cheek furrows, nasolabial folds, and marionette lines were found to have noticeably improved after 590ST BBL treatment (Figures 5 and 6).

Most of the patients reported clinical improvement in overall skin texture that was noticeable within 2 days, and the patients' median satisfaction rate at 2 months post-BBL was 2 (IQR, 2–3). Immediately after the 590ST BBL treatment, six of the nine patients (66.7%) presented transient darkening of melasma and epidermal pigmented lesions that spontaneously resolved within 1 or 2 weeks (Figure 5b, 5e, 6b, 6e). Melasma lesions on the cheeks and perioral area were moderately improved after the three sessions of 590ST BBL treatment, except for one patient (11.1%) who experienced slight worsening of melasma lesions in the periorbital and perioral areas. No other major side effects were reported.

Discussion

The optimal goal of pulsed light treatment for skin rejuvenation is overall improvement in aging-related elements, including skin wrinkles, texture, enlarged pores, facial erythema, telangiectasia, and dyspigmentation (5). In the present study, we demonstrated that BBL treatment could be effectively delivered for nonablative and noninvasive tightening of the facial and neck skin in Asian patients using three different treatment settings.

In a previous study, four to six sessions of noncoherent, polychromatic light treatment with cutoff filters of 550 or 570 nm, at fluences of 30–50 J/cm^2 and at a double- or triple-pulse frequency were delivered to the entire face: the therapeutic immediate endpoints were skin reactions of

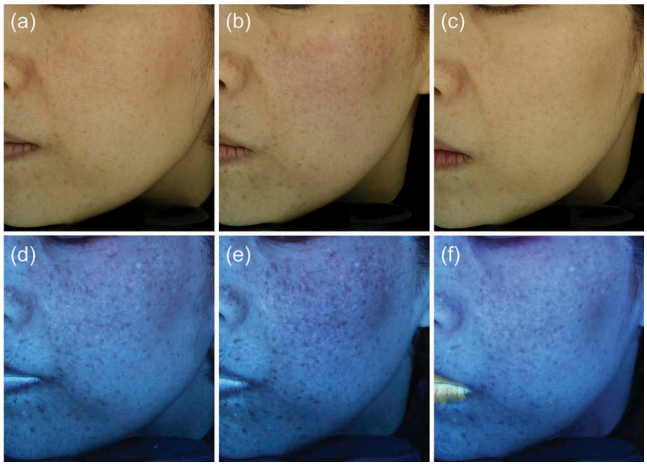

Figure 6. Photographs of a 43-year-old female patient (a, d) at baseline, (b, e) immediately after the first session of BBL treatment, and (c, f) 2 months after three sessions of BBL treatment via the 590ST cutoff filter using the constant motion technique. (b, e) Transient darkening of pigmented lesions and post-treatment erythema were found immediately after BBL treatment. (c, f) Overall skin tone and pigmented lesions were improved after the third BBL treatment, along with noticeable improvement in zygomatic wrinkles, nasolabial folds, and marionette lines. Left oblique view; photographs were taken under (a–c) normal and (d–f) ultraviolet light exposure.

mild erythema and slight darkening of pigmented lesions (5). Most of the patients therein presented remarkable improvement in all factors affecting photoaging, particularly skin wrinkles, coarseness, irregular pigmentation, and vascular lesions, along with posttreatment histologic features of new collagen formation throughout the entire dermis and the resolution of inflammatory cells and melanophages (5). The comparative clinical investigation revealed that the use of 555–590-nm cutoff filters elicited better effects for treating the irregular pigmentation of photodamaged skin with lesser side effects, compared to the 530- to 750-nm cutoff filter (11). Meanwhile, the use of the 530- to 570-nm cutoff filter was deemed more effective in the treatment of telangiectasias and diffuse erythema in aged skin (11).

Although numerous clinical studies have investigated the efficacy and safety of intense pulsed light treatment for skin rejuvenation (5,8,11–15), data on the effectiveness have proven inconstant and incomparable due to the versatility of treatment settings (e.g., wavelengths, pulse durations and intervals, and fluences). Furthermore, particularly during skin rejuvenation procedures, therapeutic outcomes can be significantly affected by the total energy accumulation within the areas and modes of BBL energy delivery. In the present study, BBL energy was delivered to the face and neck via the cutoff filters of 590ST, 695ST, and/or 800ST using the static operation and/or the constant motion delivery techniques. The static operation technique was deemed to offer the advantages of a faster heat accumulation in a limited area, better prediction, and more familiarity. Meanwhile, the constant motion delivery technique was suggested to provide the advantages of a more gradual and safer heat accumulation in a large area, better balanced delivery of BBL energy, a shorter procedure time, and a lower risk of side effects.

Some nonablative, energy-delivering devices exhibit the advantages of improving pigmented lesions and skin tone during skin rejuvenation, including long-pulse 532-nm potassium titanyl phosphate (KTP) laser, long-pulse 1,064-nm neodymium : yttrium-aluminum-garget (Nd:YAG) laser, and intense pulsed light (16–19). Furthermore, comparison studies have indicated that higher pigmentation improvement rates are achieved with rejuvenation treatments on the facial and hand skin by combination therapy with 1,064-nm Nd:YAG laser and intense pulsed light, compared to single treatment with a 1,064-nm Nd:YAG laser (18,19). The pulsed delivery of filtered BBL energy therein was suggested to target dyschromatic lesions in the epidermis and dermis, as well as vascular components, in the dermis, which resulted in a markedly brighter appearance of aging skin (19). We suggest that nonablative and noninvasive BBL treatment for skin tightening seems to have the advantages of being able to be safely combined with other noninvasive treatment modalities selectively targeting pigment and/or vascular components for better clinical outcomes.

In a previous study, three sessions of intense pulsed light treatment were delivered to participants for photorejuvenation at the cutoff ranges of 530–750 nm, at 2.5-ms double pulses with a delay time of 10 ms, and at the fluence ranges of 5.5–7.0 J/cm^2 (20). Most of the patients therein experienced significant improvement in fine wrinkles, skin texture, and enlarged pores, as well as skin tone and epidermal pigmented lesions (20). However, exacerbation of melasma lesions was also noted. In our study, most of the participants exhibited improvement of pigmented lesions and overall skin tone, and none of them presented with worsening or the appearance of melasma lesions after BBL treatments in the groups using the 800-nm cutoff filter and/or 695-nm cutoff filter. Thereby, we suggest that the use of 695-nm and 800-nm cutoff filters can reduce the risks of rebound hyperpigmentation and postinflammatory hyperpigmentation in Asian patients. Meanwhile, however, transient darkening of melasma and epidermal pigmented lesions was found, and one patient presented worsening of melasma lesions after 590ST-BBL treatment. Nonetheless, most of the patients in group 3, who were treated with BBL using the 590-nm cutoff filter, were deemed to have noticeable improvements in skin tone and pigmented lesions, along with improvement in skin texture. Nevertheless, optimized, controlled studies should be followed to evaluate the effects of BBL energy on melasma lesions for individual cutoff filters and treatment techniques during skin rejuvenation.

In conclusion, we outlined in this study three different settings of BBL treatment for nonablative and noninvasive tightening of facial and neck skin in Asian patients using (1) the 800ST-cutoff filter via a static operation technique and the 695ST-cutoff filter via a constant motion technique, (2) the 800ST-cutoff filter via a constant motion technique, and (3) the 590ST-cutoff filter via a constant motion technique. All three treatment settings elicited satisfactory clinical improvements in the signs of aging in the mid-face and lower face, particularly zygomatic wrinkles or mid-cheek furrows, nasolabial folds, perioral expression wrinkles at the cheek, and marionette lines, in Asian patients. Nonetheless, we suggest that treatment settings, including cutoff filters and delivering techniques, should be determined according to the characteristics of each patient's skin and associated pigmented disorders.

Acknowledgments

We would like to thank Duke Song (Consultant; Sciton, Palo Alto, CA, USA) for his assistance with technical support. We would also like to thank Anthony Thomas Milliken, ELS at Editing Synthase (https://editingsynthase.com) for his help with the editing of this manuscript.

Disclosure statement

The authors declare no conflicts of interest.

Funding

This work was supported by a research grant from International St. Mary's Hospital, Catholic Kwandong University College of Medicine [CKURF-201406830001].

ORCID

Sung Bin Cho http://orcid.org/0000-0001-6748-5071

References

1. Wat H, Wu DC, Rao J, Goldman MP. Application of intense pulsed light in the treatment of dermatologic disease: a systematic review. Dermatol Surg. 2014;40:359–77.
2. Bjerring P. Clinical comparison of hair reduction using the newest generation IPL and a first generation ruby laser. J Cutan Laser Ther. 2000;2:211.
3. Raulin C, Schroeter CA, Weiss RA, Keiner M, Werner S. Treatment of port-wine stains with a noncoherent pulsed light source: a retrospective study. Arch Dermatol. 1999;135:679–83.
4. DiBernardo BE, Pozner JN. Intense pulsed light therapy for skin rejuvenation. Clin Plast Surg. 2016;43:535–40.
5. Bitter PH. Noninvasive rejuvenation of photodamaged skin using serial, full-face intense pulsed light treatments. Dermatol Surg. 2000;26:835–42.
6. Kligman DE, Zhen Y. Intense pulsed light treatment of photoaged facial skin. Dermatol Surg. 2004;30:1085–90.
7. Shin JU, Lee WJ, Oh SH, Kim DY, Kim DS, Jung I, Lee JH. Altered vimentin protein expression in human dermal microvascular endothelial cells after ultraviolet or intense pulsed light treatment. Lasers Surg Med. 2014;46:431–38.
8. Babilas P, Schreml S, Szeimies RM, Landthaler M. Intense pulsed light (IPL): a review. Lasers Surg Med. 2010;42:93–104.
9. Feng Y, Zhao J, Gold MH. Skin rejuvenation in Asian skin: the analysis of clinical effects and basic mechanisms of intense pulsed light. J Drugs Dermatol. 2008;7:273–79.
10. Chang AL, Bitter PH Jr, Qu K, Lin M, Rapicavoli NA, Chang HY. Rejuvenation of gene expression pattern of aged human skin by broadband light treatment: a pilot study. J Invest Dermatol. 2013;133:394–402.
11. Bjerring P, Christiansen K, Troilius A, Dierickx C. Facial photo rejuvenation using two different intense pulsed light (IPL) wavelength bands. Lasers Surg Med. 2004;34:120–26.
12. Hedelund L, Due E, Bjerring P, Wulf HC, Haedersdal M. Skin rejuvenation using intense pulsed light: A randomized controlled split-face trial with blinded response evaluation. Arch Dermatol. 2006;142:985–90.
13. Li YH, Wu Y, Chen JZ, Gao XH, Liu M, Shu CM, Dong GH, Chen HD. Application of a new intense pulsed light device in the treatment of photoaging skin in Asian patients. Dermatol Surg. 2008;34:1459–64.
14. Kono T, Groff WF, Sakurai H, Takeuchi M, Yamaki T, Soejima K, Nozaki M. Comparison study of intense pulsed light versus a long-pulse pulsed dye laser in the treatment of facial skin rejuvenation. Ann Plast Surg. 2007;59:479–83.
15. Hantash BM, De Coninck E, Liu H, Gladstone HB. Split-face comparison of the erbium micropeel with intense pulsed light. Dermatol Surg. 2008;34:763–72.
16. Ross EV, Sajben FP, Hsia J, Barnette D, Miller CH, McKinlay JR. Nonablative skin remodeling: selective dermal heating with a mid-infrared laser and contact cooling combination. Lasers Surg Med. 2000;26:186–95.
17. Trelles MA, Alvarez X, Martín-Vázquez MJ, Trelles O, Velez M, Levy JL, Allones I. Assessment of the efficacy of nonablative long-pulsed 1064-nm Nd: YAG laser treatment of wrinkles compared at 2, 4, and 6 months. Facial Plast Surg. 2005;21:145–53.
18. Trelles M, Allones I, Vélez M, Mordon S. Nd: YAG laser combined with IPL treatment improves clinical results in non-ablative photorejuvenation. J Cosmet Laser Ther. 2004;6:69–78.
19. Oktem A, Kocyigit P. Comparison of effectiveness of 1,064-nm Nd: YAG laser and Nd: YAG laser-IPL combination treatments in hand skin rejuvenation. J Cosmet Laser Ther. 2016;18:270–74.
20. Negishi K, Kushikata N, Takeuchi K, Tezuka Y, Wakamatsu S. Photorejuvenation by intense pulsed light with objective measurement of skin color in Japanese patients. Dermatol Surg. 2006;32:1380–87.