

# TREATMENT OF PHOTOAGING WITH A VERY SUPERFICIAL ER:YAG LASER IN COMBINATION WITH A BROADBAND LIGHT SOURCE

Alexander L. Berlin MD,<sup>a</sup> Mussarrat Hussain MD,<sup>a</sup> Robert Phelps MD,<sup>b</sup> David J. Goldberg MD<sup>a,b</sup>

a. Skin Laser and Surgery Specialists of NY and NJ, New York, NY

b. Department of Dermatology, Mount Sinai School of Medicine, New York, NY

## Abstract

**Background and Objective:** Studies documenting improvement following combined laser and light-based devices are needed. The objective of this study was to evaluate clinical, histological, and ultrastructural changes in photodamaged facial skin following sequential treatment with ablative superficial erbium:YAG (Er:YAG) laser peels and nonablative intense pulsed light, or broadband light (BBL), treatments.

**Study Design/Materials and Methods:** Fifteen subjects with photodamaged facial skin and Fitzpatrick skin types I to III underwent 3 monthly treatments with the Profile™ system (Sciton, Inc, Palo Alto, CA) utilizing very superficial MicroLaserPeel™ settings of 2.5 to 5.0 J/cm<sup>2</sup> and BBL™ settings of 515-, 560-, or 590-nm filters, 10-msec pulse duration, and fluences of 12 J/cm<sup>2</sup>. Five subjects underwent pre- and post-treatment postauricular skin biopsies for evaluation of treatment-induced light and electron microscopic changes.

**Results:** Twelve subjects completed the study. Both blinded evaluator and subject assessment of clinical changes documented significant improvement in photodamaged skin, with the greatest improvement achieved in overall appearance and epidermal dyspigmentation. These results were largely maintained at 3 months following the last treatment. Light microscopy showed changes in the epidermis, collagen, and elastic fibers consistent with a wound repair mechanism to the depth of 250 to 350 microns. Electron microscopy revealed a slight decrease in the average collagen fiber thickness, pointing to an increase in type III collagen.

**Conclusion:** A protocol utilizing multiple combined superficial Er:YAG ablative treatments and nonablative BBL treatments lead to a significant improvement in the clinical signs of photodamaged skin, with histological and ultrastructural evidence of new collagen formation.

## Introduction

As various laser and light-based devices are being combined in clinical practice for their additive effect, studies documenting improvement following such treatments need to be undertaken. Both superficial ablative treatments using erbium:YAG laser and nonablative treatments using intense pulsed light (IPL)—also known as broad-band light (BBL™)—have been successfully used for facial photorejuvenation.<sup>1,2</sup> In addition to the clinical improvement noted with each of these devices, histological and ultrastructural evidence of new collagen formation and other changes associated with the wound repair mechanism have also been demonstrated.<sup>3</sup> Since both of these treatment options result in minimal, if any, downtime and adverse effects, they represent attractive options for facial rejuvenation.

This study was undertaken in order to evaluate clinical improvement in photodamaged facial skin using multiple sequential very superficial ablative Er:YAG laser peels combined with nonablative full-face BBL treatments. In addition, histological and ultrastructural examination of biopsy specimens was performed to assess the treatment-induced microscopic changes.

## Materials and Methods

Fifteen female subjects with photodamaged facial skin, ranging in ages from 30 to 60 years and Fitzpatrick skin types I to III, were enrolled in the study. An explanation of the risks, benefits, and potential complications was given to the subjects, and written informed consent was obtained.

Subjects with a history of herpes simplex in the treatment areas were given prophylactic oral antiviral agents prior to the procedure. Anesthesia was achieved with a topical anesthetic cream applied for 1 hour prior to each treatment. All subjects were then treated using the Profile™ multiapplication system (Sciton, Inc, Palo Alto, CA). Specifically, the Er:YAG laser was used in a scanning ablative mode, also known as MicroLaserPeel™, with a 6-mm spot size, 2.5 J/cm<sup>2</sup> for the first session and 5.0 J/cm<sup>2</sup> thereafter, and 30% pulse overlap to complete one full pass over the entire face. Subsequently, a chilled gel was applied to the face, and the BBL source was used in a nonoverlapping pattern with a 515-, 560-, or 590-nm filter, depending on the level of epidermal dyspigmentation, in a single-pulsed mode with 10-msec pulse duration and fluence of 12 J/cm<sup>2</sup> using contact cooling.

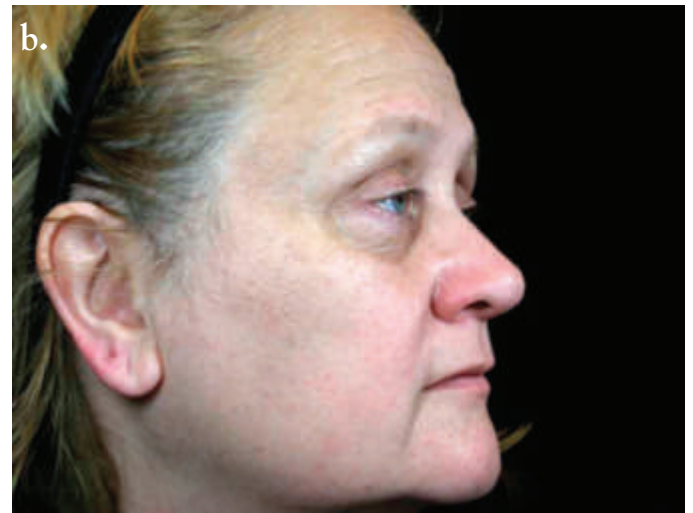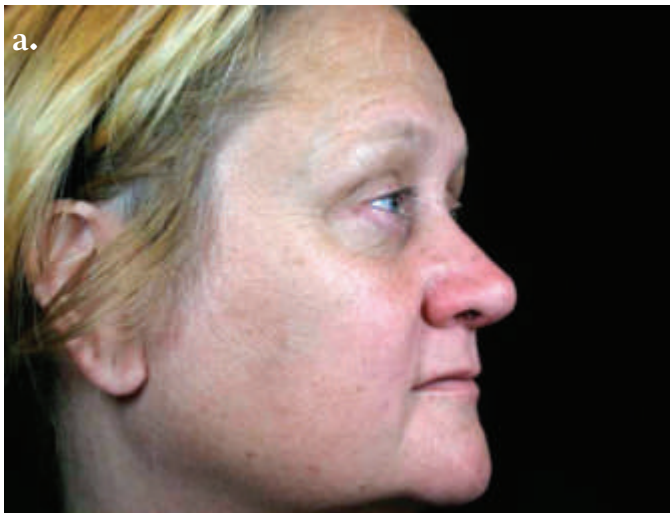A petrolatum-based ointment was then applied to the entire face and subjects were instructed on proper wound care. Additionally, the subjects were instructed on proper sun protection and the use of broad-spectrum sunscreens. A total of 3 sessions were performed at 1-month intervals, with additional follow-up visits at 1 and 3 months following the last treatment.

Assessment of clinical improvement was performed using blinded observer evaluation of photographs obtained pretreatment and at 1 and 3 months following the last treatment. Pre- and post-treatment photographs were randomly placed side by side and the blinded observer was asked to assign the difference, in percents, between the 2 photographs in the following aspects of photodamaged skin: overall appearance, epidermal dyspigmentation, rhytides, and skin laxity. In addition, at 1 and 3 months following the last treatment, sub-

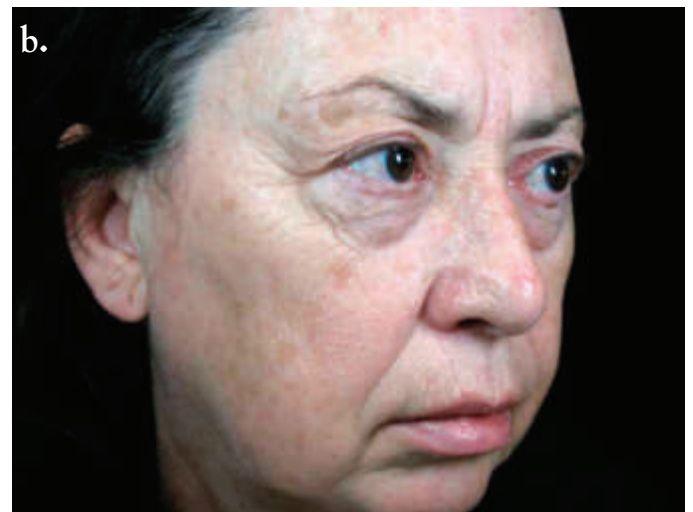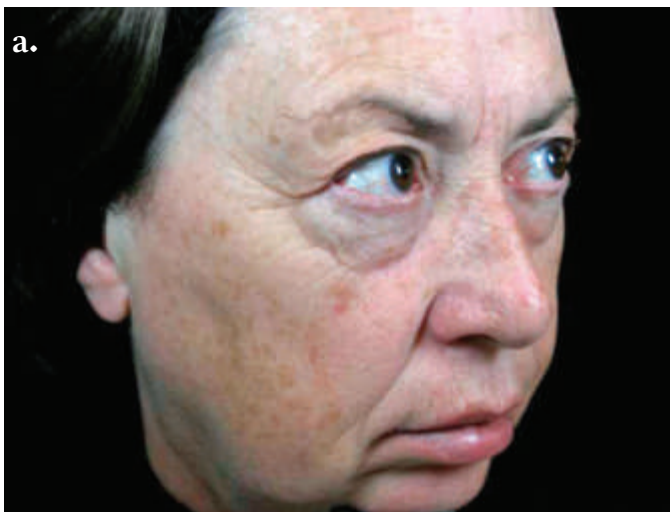jects completed standardized questionnaires on their perceived percent improvement in the same categories.

Finally, 5 subjects underwent postauricular biopsies both before and 3 months after the final treatment. In these subjects, a pretreatment biopsy was performed on the immediate postauricular area approximately corresponding to the level of the external ear canal on a randomly assigned side. The contralateral location was then treated over the same 3 sessions according to the protocol used on the rest of the face. A biopsy was performed 3 months following the last treatment in a similar manner to the pretreatment side. All biopsy specimens were split for processing for light and electron microscopy. For the electron microscopy, sampling bias was minimized by obtaining 2 to 3 sections for each specimen and by analyzing 2 to 3 areas within each section. All specimens were analyzed by a single blinded dermatopathologist for treatment-induced changes.

**Figure 1.** A 52-year-old female subject a) pretreatment and b) at 3 months following the last treatment, showing good improvement in epidermal dyspigmentation and mild improvement in fine rhytides.



**Figure 2.** A 61-year-old female subject a) pretreatment and b) at 3 months following the last treatment, showing good improvement in epidermal dyspigmentation and minimal to mild improvement in fine rhytides.





## Results

Of the 15 enrolled subjects, 12 completed the study. Three subjects dropped out for the following reasons: one subject moved to a different state, one subject had botulinum toxin injection during the follow-up period, and one subject was lost to follow-up.

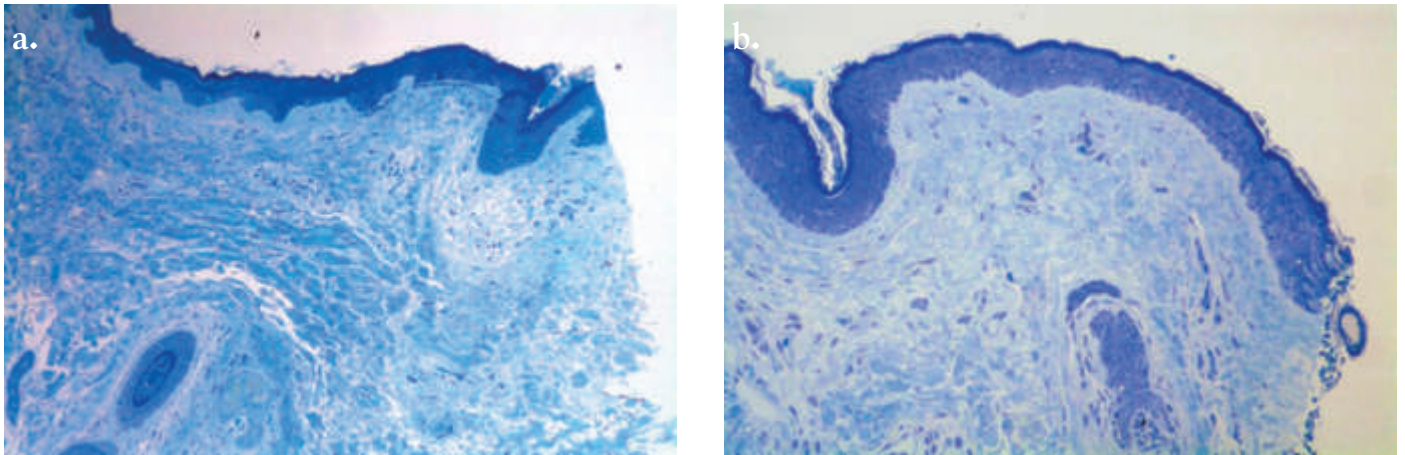
Following the procedure, most subjects reported only mild erythema lasting up to one week and scaling that typically resolved in 3 to 4 days. No unexpected adverse effects, such as infections, pigmentary alterations, or scarring, were observed in the study.

At one month follow-up, blinded evaluator assessment of photographs showed an average improvement in overall appearance of 46.3%, in epidermal dyspigmentation of 54.2%, in rhytides of 25.8%, and in skin laxity of 12.9%. At 3 months, average improvement in overall appearance was rated at 45.6%, in epidermal dyspigmentation at 50.6%, in rhytides at 22.8%, and in skin laxity at 13.3% (Figures 1 and 2).

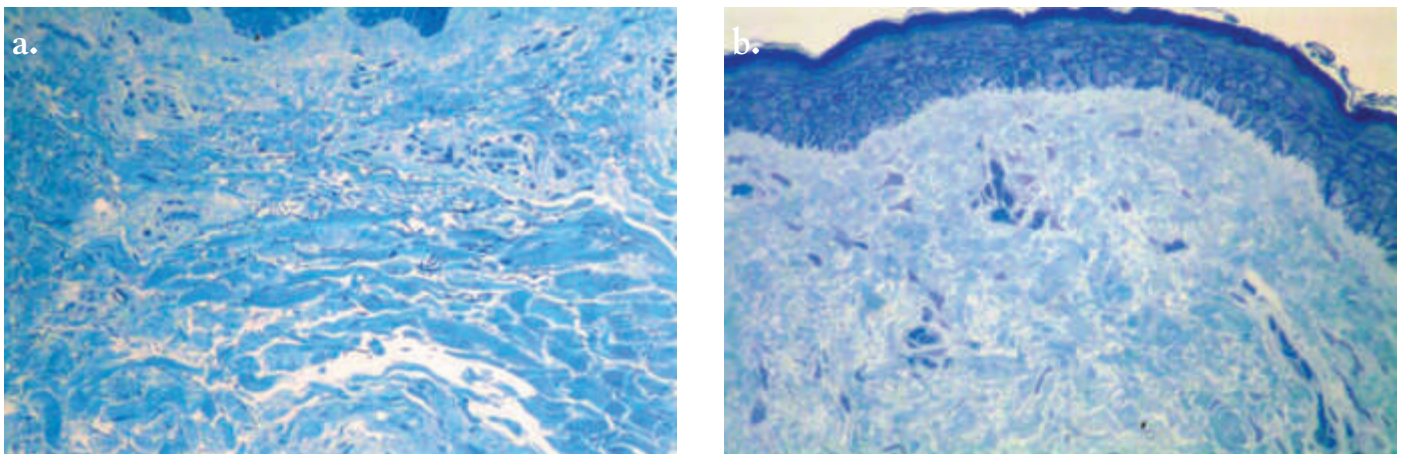
According to subject questionnaires, average improvement in overall appearance at one month following the last treatment was 53.5%, dyspigmentation of 64.0%, rhytides of 32.5%, and skin laxity of 31.0%. Overall subject satisfaction with the procedure and its results at one month follow-up was 64.3%. At 3 months, the average improvement in overall appearance as rated by the subjects was 60.0%, with 60.0% improvement in dyspigmentation, 36.7% in rhytides, and 33.9% in skin laxity. Overall satisfaction at 3 months following the last treatment was 63.1%.

Histological analysis of the biopsy specimens revealed post-treatment flattening of the epidermal rete ridges, together with a mild perivascular mononuclear infiltrate. Thickened and disorganized elastic fibers, consistent with actinic damage, were evident in pretreatment biopsy specimens in the papillary dermis, but were no longer present in the post-treatment biopsies to the depth of 250 to 350 microns (Figures 3 and 4). Ultrastructurally, the average collagen fibril thickness decreased from 60 nm before treatment to 55 nm at 3 months following the last treatment (Figure 5).


**Figure 3.** Biopsy specimen **a)** pretreatment and **b)** at 3 months following the last treatment, showing flattening of the epidermal rete ridges (methylene blue, original magnification x 20).



**Figure 4.** Biopsy specimen **a)** pretreatment, showing thickened and disorganized elastic fibers in the papillary dermis, **b)** no longer present at 3 months following the last treatment (methylene blue, original magnification x 40).



**Figure 5.** Ultrastructural analysis of a biopsy specimen showing a decrease in the average collagen fibril thickness from a) 60 nm pre-treatment to b) 55 nm at 3 months following the last treatment.



## Discussion

At 2940 nm, light emitted by the Er:YAG laser is near the largest absorption peak of the water molecule and causes vaporization of water-containing tissues. A very convenient feature of the Er:YAG laser in a purely ablative mode is its predictable ablation of 2 to 4 microns of tissue per 1 J/cm<sup>2</sup> of fluence. Thus, in the current study, facial skin was being ablated to the depth of approximately 10 to 20 microns, far less than the average facial epidermal thickness of 80 to 100 microns. Unlike that seen with the CO<sub>2</sub> laser, the residual thermal damage, or thermal diffusion, associated with the Er:YAG laser in ablative mode is also minimal, estimated to be between 10 and 50 microns.<sup>4,5</sup> Thus, with most of the epidermal thickness unaffected during a typical superficial laser peel session, healing time and risk of adverse effects, including infections, dyspigmentation, and scarring, are minimized. Nonetheless, clinical improvement in photodamaged skin following several such treatments has now been clearly documented.<sup>1,6</sup>

IPL sources, such as BBL, utilize flashlamps that typically emit in the 400- to 1400-nm range. The resulting noncoherent light can then be filtered to match absorption characteristics of the desired tissue target. Of note, IPL sources were among the first devices clinically proven to result in nonablative photorejuvenation.<sup>2</sup> Histological data was published soon thereafter and documented new collagen formation in the papillary dermis consistent with a wound repair mechanism following such treatment.<sup>3</sup>

In the current study, the 2 clearly effective treatment modalities were combined. Although the improvement in epidermal dyspigmentation was highest, other signs of photodamaged and aging skin were also affected by the combined modalities. Although not divided into separate categories in the present study, cutaneous characteristics, such as erythema, skin texture, and luster, also improved following treatments. This is reflected in the high percentage of change in the overall appearance as rated both by subjects and blinded observer. It

is unclear, however, whether the clinical effect from the combined treatments was simply additive or synergistic due to the improved penetration of noncoherent light following superficial ablation.

Examination of biopsy specimens documented evidence of a wound repair 3 months following the last treatment. Especially striking was the change in the distribution of aberrant elastic fibers, with those in the papillary and upper reticular dermis not apparent in the post-treatment specimen. Although an indirect measurement of optical penetration of light into the skin, we considered the depth of changes in the elastic fibers (between 250 and 350 microns) to be the vertical extent of photothermolysis and subsequent wound repair. The additional ultrastructural finding of a decrease in the average thickness of collagen fibrils is indirect evidence of an increase in the ratio of collagen III to collagen I. Collagen III fibrils are slightly thinner than collagen I and, although abundant in fetal skin, collagen III is mostly present in the adult skin in the papillary dermis and during the wound repair process, where it is subsequently replaced by collagen I in the later remodeling phase. Of note, the complete extent of neocollagenesis may take 4 to 6 months to fully appreciate following an intervention. Thus, although already impressive in the current study, the amount of new collagen deposition may be even higher if the follow-up period is extended to 6 months after the last treatment.

## Conclusion

In the present study, we demonstrated that multiple combined superficial Er:YAG laser ablative and nonablative noncoherent light treatments can lead to a significant improvement in the signs of photodamaged and aging facial skin. Additionally, microscopic and ultrastructural evidence of wound repair to the depth of 250 to 350 microns was demonstrated. Future studies may determine whether varying ablative and nonablative settings, as well as longer post-treatment follow-up, may lead to even more impressive results.

## Acknowledgement

This study was presented at the 27th Annual Meeting of the American Society for Lasers in Medicine and Surgery in Grapevine, Texas, April 2007.

## Disclosure

This study was supported, in part, by a research grant from Sciton, Inc.

## References

1. Pozner JN, Goldberg DJ. Superficial erbium:YAG laser resurfacing of photodamaged skin. *J Cosmet Laser Ther.* 2006;8:89-91.
2. Bitter PH. Noninvasive rejuvenation of photodamaged skin using serial, full-face intense pulsed light treatments. *Dermatol Surg.* 2000;26:835-843.
3. Goldberg DJ. New collagen formation after dermal remodeling with an intense pulsed light source. *J Cutan Laser Ther.* 2000;2:59-61.
4. Walsh JT Jr, Flotte TJ, Deutsch TF. Er:YAG laser ablation of tissue: effect of pulse duration and tissue type on thermal damage. *Lasers Surg Med.* 1989;9:314-326.
5. Hohenleutner U, Hohenleutner S, Baumler W, Landthaler M. Fast and effective skin ablation with an Er:YAG laser: determination of ablation rates and thermal damage zones. *Lasers Surg Med.* 1997;20:242-247.
6. Khatri KA, Machado A, Magro C, Davenport S. Laser peel: facial rejuvenation with a superficial erbium:YAG laser treatment. *J Cutan Laser Ther.* 2000;2:119-123.

### ADDRESS FOR CORRESPONDENCE

David J. Goldberg MD  
Skin Laser & Surgery Specialists of NY/NJ  
115 E. 57th Street, Suite 702  
New York, NY 10022